DOI: 10.1111/jocs.13204

SURGICAL TECHNIQUE

WILEY Journal of Cardiac Surgery

Safe sternal reentry in all age groups with the Rultract Resternotomy Retractor™

Karl Reyes MD | Lisa Schnabel RNFA | Susan Cooke PAC | Mark Bleiweis MD

Departments of Surgery and Pediatrics, Congenital Heart Center, University of Florida — Shands Hospital, Gainesville, Florida

Correspondence
Karl Reyes MD, Departments of Surgery and Pediatrics, University of Florida – Shands Hospital, 1600 Archer Road, Gainesville, FL 32608.
Email: karl.reyes@peds.ufl.edu

Abstract

In patients undergoing repeat sternotomy, the risk of injury to cardiac structures can be reduced by utilizing a technique that provides sustained visualization of structures adherent to underside of the sternum. We discuss the use of a retractor specifically designed for this purpose: the Rultract Resternotomy Retractor™.

KEYWORDS
reoperations, resternotomy, retractor

1 | INTRODUCTION

Reoperative cardiac surgery carries inherent risks from sternal reentry. These risks increase as the number of previous surgeries increase and are present regardless of age group or type of procedure.[1–2] Multiple strategies for sternal reentry have been proposed.[3–5] We have developed a technique for sternal reentry that is adaptable to both pediatric and adult congenital patients with the use of a retractor that was developed by Rultract Inc. (Cleveland, OH). This Resternotomy Retractor allows us to have a stable sternal reentry platform with clear and sustained visualization of the structures on the underside of the sternum.

2 | TECHNIQUE

A computed tomography scan is routinely performed, and the relationship of major vascular structures to the sternum are delineated. In the operating room, the patient is placed in the supine position under general anesthesia. Invasive monitoring lines and defibrillator pads are placed, both groins are exposed, and in high risk infants, the right neck is also prepped and exposed.

A midline incision is made over the previous scar and extended approximately 1–2 inches below the xiphoid process. The anterior sternum is exposed and sternal wires are cut and removed. A subxiphoid plane is developed widely starting under the fascia and costal margins. The Skyhook Retractor (Rultract Inc.) is now placed on the operating table bedrail (Figure 1). The Rultract Resternotomy Retractor™ is then attached and its rakes are placed with each rake positioned on opposite sides under the costal margin. The resternotomy retractor rakes are now lifted by rotating the top ratchet, and then separated by rotating the separator wheel until the subxiphoid area and distal sternum are exposed (Figure 2). The patient is then placed in Trendelenburg position, and a waitlander or cerebellar retractor is placed to separate the fascia and rectus muscle. The underside of the sternum in the midline is now clearly visualized and facilitates subxiphoid dissection (Figure 3). Electrocautery is used at low setting and a suction retracts tissues inferiorly for dissection and separation of the mediastinum from the posterior table of the sternum. It may be necessary to enter both pleural cavities in order to dissect laterally to medially as needed. Once the dissection with electrocautery can no longer be performed because it is unreachable by the electrocautery tip, the sternum is partially divided at the midline using a pencil type oscillating saw with an angled rectangular blade. A thin malleable retractor is placed underneath the sternum during division to protect the mediastinal structures. After partial division of the sternum, the resternotomy retractor is lowered and the blades are repositioned across each other on the divided sternum. The retractor is then raised, and the rakes are again separated using the separator wheel. Dissection underneath the sternum is continued until the sternum is fully divided. Because the blades are on opposite sides, it is not

FIGURE 1 The Rultract Skyhook System™. Attachments are connected to the lower hook and lifted by rotating the top rachet

FIGURE 2 Rultract Resternotomy Retractor™ with opposing rakes that can be spread apart with the separator wheels

necessary to lower and remove the retractor during division of the sternum. If dense adhesions are present, a subperiosteal plane is created and periosteum is left on the surface of the heart. Once the sternum is completely divided, the retractor is lowered and the body is returned to the supine position. A standard sternal retractor is then placed, and the heart and mediastinal structures are further dissected in preparation for the operative procedure.

3 | DISCUSSION

In 2012, we requested modifications to the current Rultract Skyhook IMA Retractor™ to facilitate sternal reentry for reoperative cardiac procedures. Previous to this, the original IMA retractor was already being used to aid in cardiac reoperations by lifting the xiphoid for subxiphoid dissection; however, the rakes were positioned underneath and in the middle of the sternum. In this position, the rake itself often impaired visualization, and the rake needed to be removed every time the oscillating saw was used. With the new retractor, the rakes are on opposite sides of the costal margin, and can be spread apart. Specific advantages of this retractor include:

1. Direct visualization of the underside of the sternum. The rakes are positioned on opposite sides of the costal margin and the patient placed in Trendelenburg position allowing full visualization of the subxiphoid space and the underside of the sternum. This makes for a very stable dissecting platform.
2. Reduced need for positioning and repositioning. Since sternotomy with the oscillating saw can be performed in between the rakes, dissection can be performed with little interruption. The rakes of the retractor are only repositioned to the mid-sternum once dissection is no longer possible either because tissues are out of reach of the electrocautery tip or if visualization of the superior-most portion of the sternum becomes poor. Because the rakes can be separated in a controlled a fashion, a wide plane of dissection can be performed underneath the sternum.
3. Minimized error and inadvertent injury from fatigue. Invariably, both the surgeon and assistants would need to lift retractors manually to facilitate dissection. This can lead to injury if positioning cannot be sustained or if there is any unexpected movements. Cardiac structures can also be injured if vigorous lifting is done while the structures are adhered to the sternum. This retractor helps avoid those injuries.

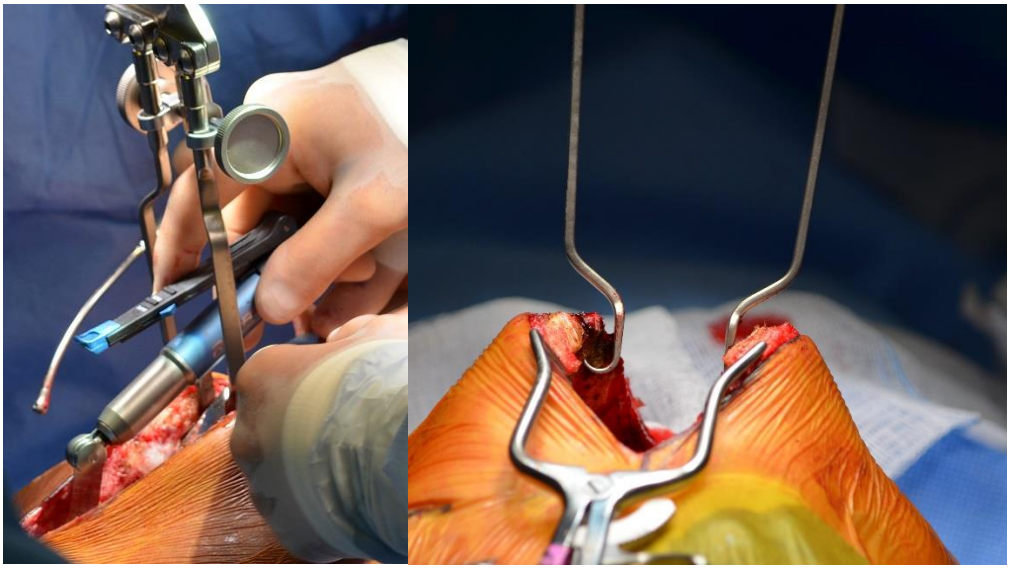

FIGURE 3 The rakes are positioned on opposite sides of the costal margin and the sternum is gradually separated. Lifting of the xiphoid and distal sternum creates a wide field of visualization underneath the sternum for electrocautery dissection

4. Applicable to all patients ages. The variety of retractor sizes (18, 12, and 8 mm) permits use of this retractor for all patients in all age groups.

This approach has become the standard approach for sternal reentry at our institution. Programs adopting this technique can utilize the standard Skyhook retractor system currently in use for internal mammary artery harvest and exchange the mammary rakes for the resternotomy retractor piece (Figure 2) which is now currently available. Since January 2013, we have performed 363 redo sternotomies in both adult and pediatric congenital cardiac cases using this retractor. Preemptive groin exposure and peripheral cannulation is performed when cardiac structures are densely adherent, and we have not required the need for emergent peripheral cannulation using this approach.

CONCLUSION

Reoperative sternotomy with the Rultract Resternotomy Retractor™ provides a safe, reliable, and consistent method for sternal reentry. This technique can be used in all age groups of patients with both acquired and congenital heart disease, irregardless of the number of previous sternotomies.

CONFLICT OF INTEREST

None.

ORCID

Karl Reyes http://orcid.org/0000-0002-1883-1297

REFERENCES

1. Jacobs JP, Mavroudis C, Quinteenza JA, et al. Reoperations for pediatric and congenital heart disease: an analysis of the Society of Thoracic Surgeons (STS) congenital heart surgery database. Semin Thorac Cardiovasc Surg Pediatr Card Surg Ann. 2014;17:2–8.
2. Kirshbom PM, Myung RJ, Simsic JM, et al. One thousand repeat sternotomies for congenital cardiac surgery: risk factors for reentry injury. Ann Thorac Surg. 2009;88:158–161.
3. Black A, Alexander JA, Reoma J, et al. Safe sternal reentry in patients with large thoracic aortic pseudoaneurysms. Ann Thorac Surg. 2014;97:705–707.
4. Eddy AC, Miller D, Johnson D, et al. Anterior sternal retraction for reoperative median sternotomy. Am J Surg. 1991;5:556–559.
5. Gazzaniga AB, Palafox BA. Substernal thoracoscopic guidance during sternal reentry. Ann Thorac Surg 2001;72:289–90.

How to cite this article: Reyes K, Schnabel L, Cooke S, Bleiweis M. Safe sternal reentry in all age groups with the Rultract Resternotomy Retractor™. J Card Surg. 2017;1–3. https://doi.org/10.1111/jocs.13204